

PRIME

Sep/Oct 2018
Volume 8 | Issue 5

INTERNATIONAL JOURNAL OF AESTHETIC AND ANTI-AGEING MEDICINE

**FACIAL
CONTOUR**
INJECTION TECHNIQUES

**COMBINATIONAL
ACTIVES**
TO REJUVENATE FACIAL SKIN

**HAIR
TRANSPLANTATION**
FOR FEMALE ALOPECIA

Reducing
POST-PROCEDURAL
INFLAMMATION

THE ROLE OF HYALURONIC INJECTIONS IN EYELID REJUVENATION

Jamil El-Rahi, MD, discusses the results of his study combining hyaluronic acid with succinic acid to improve wrinkles and treat dark circles in the periorbital area



JAMIL EL RAHI, MD, Plastic & Reconstructive Surgery, Head of Plastic Surgery Dpt, Raee Hospital, Lebanon

email: drjamilraee@gmail.com

ABSTRACT

Infraorbital dark circles represent a common and multifactorial challenge in the world of aesthetic medicine. They are the result of various factors, including deep facial anatomy, soft tissue changes, as well as contributions from the skin.

As we age, the thin skin of the lower eyelid undergoes continuous changes manifested by increased wrinkling, texture and colour changes (dyschromia). These changes interfere with the facial appearance, giving the patient a tired look. Many modalities of lower eyelid rejuvenation have been described. Surgical blepharoplasty is indicated to treat prolapse of orbital fat and hypertrophy of the orbicularis muscle. Non-surgical options, including chemical peels, laser skin resurfacing, radiofrequency tightening, intense pulsed light, filler injections, and botulinum toxin are described.

Thirty female patients between 20-60 years of age are included in this study. They are subject to three sessions of hyaluronic acid (18 mg/ml)/succinic acid (16 mg/ml) injections at 2 weeks interval in the periorbital area with an average of 0.5 cc per side for each session.

Levels of skin hydration, pigmentation and wrinkling were measured using a specific skin analysis machine.

At the end of three sessions, the patients were asked to fill a questionnaire regarding the pain during the procedure, the swelling post procedure, the degree of improvement they felt regarding colour changes, texture and wrinkles, and whether they would undergo the treatment again and if they will recommend it to a friend or relative.

Hyaluronic acid/succinic acid combination injection under the eyes has shown to be an effective and safe method for treating the dark circles and improving the fine wrinkles in the periorbital area. The most common complaint from the patients was the swelling after the procedure, which in some cases extended to one week.

THE DEMAND FOR PERIORBITAL REJUVENATION IS INCREASING by the day. More patients are seeking aesthetic clinics to get rid of their periocular wrinkles, to fill the infraorbital hollowness, and to improve their dark circles.

Despite the various methods and techniques used, results are not always satisfactory. Depending on each case, the treatment can be surgical (blepharoplasty with fat reposition) or non-surgical (hyaluronic acid [HA], botulinum toxin, peeling, and lasers).


In this study, the author presents his experience using the injection of HA/succinic acid (SA) combination and its effect on the main periocular signs.

KEYWORDS

Hyaluronic acid, Succinic acid, Periorbital, Rejuvenation, Dark circles.

Materials and methods

From June 2017 to January 2018, 30 consecutive female patients between 30 and 60 years of age underwent HA/succinic acid injections in the periorbital area. Patients with



a history of any periorbital treatment performed in the last year were excluded from the study (previous blepharoplasty, HA injection, or botulinum toxin).

The patients were subject to three sessions of non-cross-linked HA 18mg/ml and succinic acid 16mg/ml injection with 2 weeks interval between sessions. An average of 0.5cc was injected per side.

Photos were taken before the start of treatment and 2 weeks after the last session of injection. A specific skin analysis using a skin analysis machine was employed at the same time to determine hydration, pigmentation, and wrinkles. Baseline levels of skin hydration, elasticity and melanin were measured before beginning the treatment and then 2 weeks after the last session of injection. Patients were also asked to answer a questionnaire 2 weeks after the last session.

“ From June 2017 to January 2018, 30 consecutive female patients between 30 and 60 years of age underwent HA/succinic acid injections in the periorbital area. ”

Technique

Application of local anaesthetic cream was given 45 minutes before the procedure. Disinfection using chlorhexidine swab was also performed. A total of 0.5cc of HA/SA combination was injected per side, in intradermic papules separated by 5mm. The patients were advised not to massage the papules, as these non-crosslinked HA papules usually disappear after 24 hours.

Results

A total of 30 female patients were subject to three sessions of hyaluronic acid/succinic acid injections, with 2 weeks interval between sessions.

Analysis of the skin testing machine results showed an increase in average hydration and elasticity levels and a decrease in average melanin levels between day 0 and day 45 (2 weeks after the last session) ▷



“Blepharoplasty with fat repositioning is a well known and effective tool to improve hollowness and to remove some extra redundant skin from the lower eyelid, but it doesn't address the thin skin and the pigmentation already present as well as the fine periocular wrinkles.”

▷ Average hydration level increased from 29.5 at the start of the treatment to 61.6. Average elasticity went from 35.5 to 46.6. Average melanin level measure in the periorbital area decreased from 85.3 to 70.4.

Results of the questionnaire were analysed. Eighteen patients (60%) described the pain as moderate, and only one patient (3%) reported severe pain on injection. Twenty (66%) patients reported periorbital swelling between 1-3 days, two patients (6%) suffered from swelling for 7-9 days. Eight patients (27%) described a significant colour improvement, 15 patients (50%) reported moderate improvement. Eighteen patients (60%) described a mild improvement in texture. Nine patients (30%) described a significant improvement of periocular wrinkles, 14 patients (47%) described a mild improvement. A total of 83% of patients would undergo the treatment again, and 77 % would recommend it to a friend or relative.

Discussion

Infraorbital dark circles represent a common and multifactorial challenge in the world of aesthetic medicine. They are the result of various factors, including deep facial anatomy, soft tissue changes, as well as contributions from the skin.

An understanding of the deep (orbital fat pads, orbicularis muscle) and superficial anatomy (the lower eyelid skin) is crucial to the management of this complex entity. The eyelid skin, being the thinnest skin of our body, is directly attached to the underlying orbicularis muscle underneath with no subcutaneous tissues in between. This direct relation between muscle and skin leads to dark circles (slow blood flow, muscle directly under thin skin) and to the presence of fine wrinkles in the periorbital areas.

Different tools are used to counteract these changes. Blepharoplasty with fat repositioning is a well known and effective tool to improve hollowness and to remove some extra redundant skin from the lower eyelid, but it doesn't address the thin skin and the pigmentation already present as well as the fine periocular wrinkles.

Botulinum toxin only addresses the fine expression wrinkles and should be used with caution under the eyes.

Hyaluronic acid filler, when used to fill the tear trough, gives excellent results when properly injected. It has a positive effect on dark circles due to tear trough deformity, but this same filler cannot be used for the more superficial wrinkles due to the Tyndall effect.

Nano fat injection is another tool that is being used more frequently, and it has a positive effect on dark circles related to skin pigmentation.

Lasers and peeling agents, as any other type of skin resurfacing, has a positive effect on skin pigmentation and fine wrinkles, but again these should be used with caution in the eyelid for fear of ectropion.

In the author's study, the aim was to evaluate the effectiveness of hyaluronic and succinic acid combination for the treatment of dark circles as well as fine wrinkle and skin quality. ▷

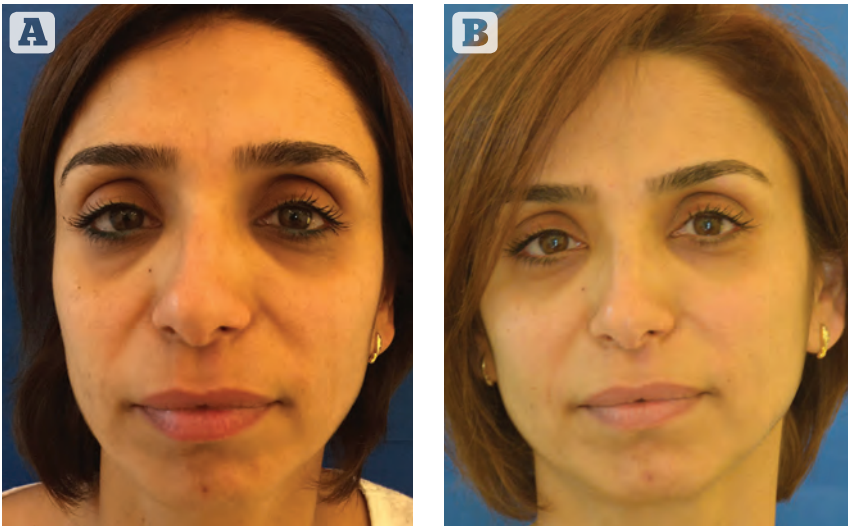

Figure 1 (A) Before treatment (B) 2 weeks after third session

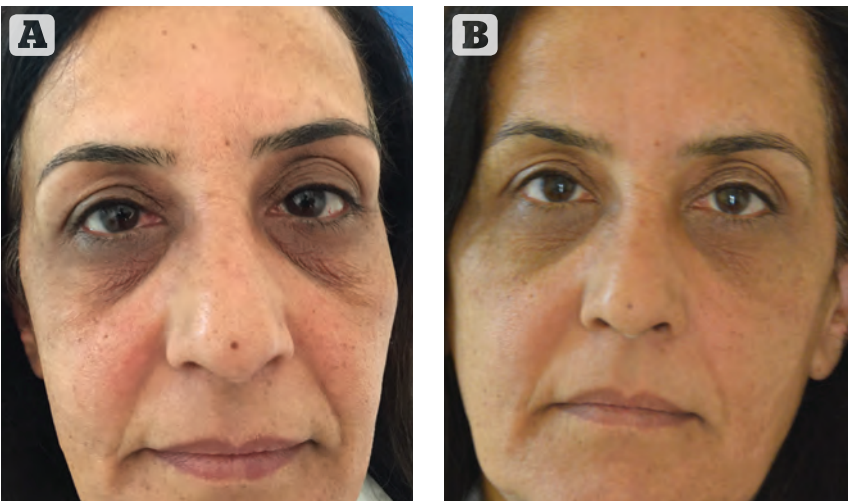

Figure 2 (A) Before treatment (B) Improvement in texture and color noted at day 45

“When combined, HA and sodium succinate act synergistically to stimulate fibroblast cells to increase (in both number and metabolic activity) with a more significant effect when compared to HA mono-component therapy.”

References

1. Ramos-Torrecillas J, Luna-Bertos Ed, Manzano-Moreno FJ, García-Martínez O, Ruiz C. Human fibroblast-like cultures in the presence of platelet-rich plasma as a single growth factor source: clinical implications.
2. Zarubina IV, Lukk MV, Shabanov PD. Antihypoxic and antioxidant effects of exogenous succinic acid and aminothiol succinate-containing antihypoxants. *Bull Exp Biol Med* 2012; 153(3): 336-9
3. Cohen BE, Elbuluk N. Microneedling in skin of color: A review of uses and efficacy. *J Am Acad Dermatol* 2016; 74(2): 348-55
4. Berezoskiy, V.A, et al, 'Connected to the question of human skin physiological renovation', *The Ukrainian magazine of dermatology, venereology & cosmetology*, 3(2011).
5. Turlier, V, et al, 'Association between collagen production and mechanical stretching in dermal extracellular matrix: in vivo effect of cross-linked hyaluronic acid filler, A randomised, placebo-controlled study', *J Dermatol Sci*. 69(2013), pp.187-94.

Key points

- From June 2017 to January 2018, 30 consecutive female patients between 30 and 60 years of age underwent HA/ succinic acid injections in the periorbital area
- A total of 30 female patients were subject to three sessions of hyaluronic acid/succinic acid injection, with 2 weeks interval between sessions
- A total of 83% of patients would undergo the treatment again, and 77 % would recommend it to a friend or relative

▷ Hyaluronic acid

The significance and effects of injecting HA into the skin is well known. Hyaluronic acid is a natural glycosaminoglycan existing in the body. It is known to add volume and increase the amount of collagen in the dermis through fibroblast stimulation as well as water retention, therefore, increasing skin turgor and hydration¹.

Multiple findings suggest that succinic acid also has the ability to reduce pigmentation². Succinic acid is a dicarboxylic acid with metal chelating potential, with a particular affinity to copper³. Copper is present in the active site of tyrosinase and has a vital role in the activity of this enzyme.

Combining HA and sodium succinate

When combined, HA and sodium succinate act synergistically to stimulate fibroblast cells to increase (in both number and metabolic activity) with a more significant effect when compared to HA mono-component therapy⁴. This should then translate to the restoration of cells, an increase in skin elasticity, firmness and tightness, improved colour and texture, as well as a reduction in the signs of ageing and fatigue⁵.

In the current study, most of the patients were happy with their treatment, with the majority saying that they would undergo the treatment again and they would recommend it to a friend or relative. Subjectively, an improvement was noted in all parameters regarding hydration, pigmentation and fine wrinkle improvement. The main complaint was prolonged swelling in some cases, and this is mainly due to the water retention of hyaluronic acid and to the use of multiple injection techniques in the very delicate eyelid skin.

There was not a long follow-up period using this protocol so the author is unable to give their recommendation concerning the duration of effects and the need to repeat the treatment.

The author will be working in the future on a new study to compare the effects of this combination with the results of nano-fat for dark under-eye circles.

Conclusion

In the study, combining hyaluronic and succinic acid for injection in the eyelid region was found to be an effective tool to improve dark circles, reduce fine wrinkles, and improve skin texture. The main adverse effect after this treatment was prolonged swelling in some cases. No severe side-effects were noted. More time is still needed for the follow-up to determine the durability of this treatment.

▶ **Declaration of interest** None

▶ **Figures 1 & 2** © DrEl-Rahi